

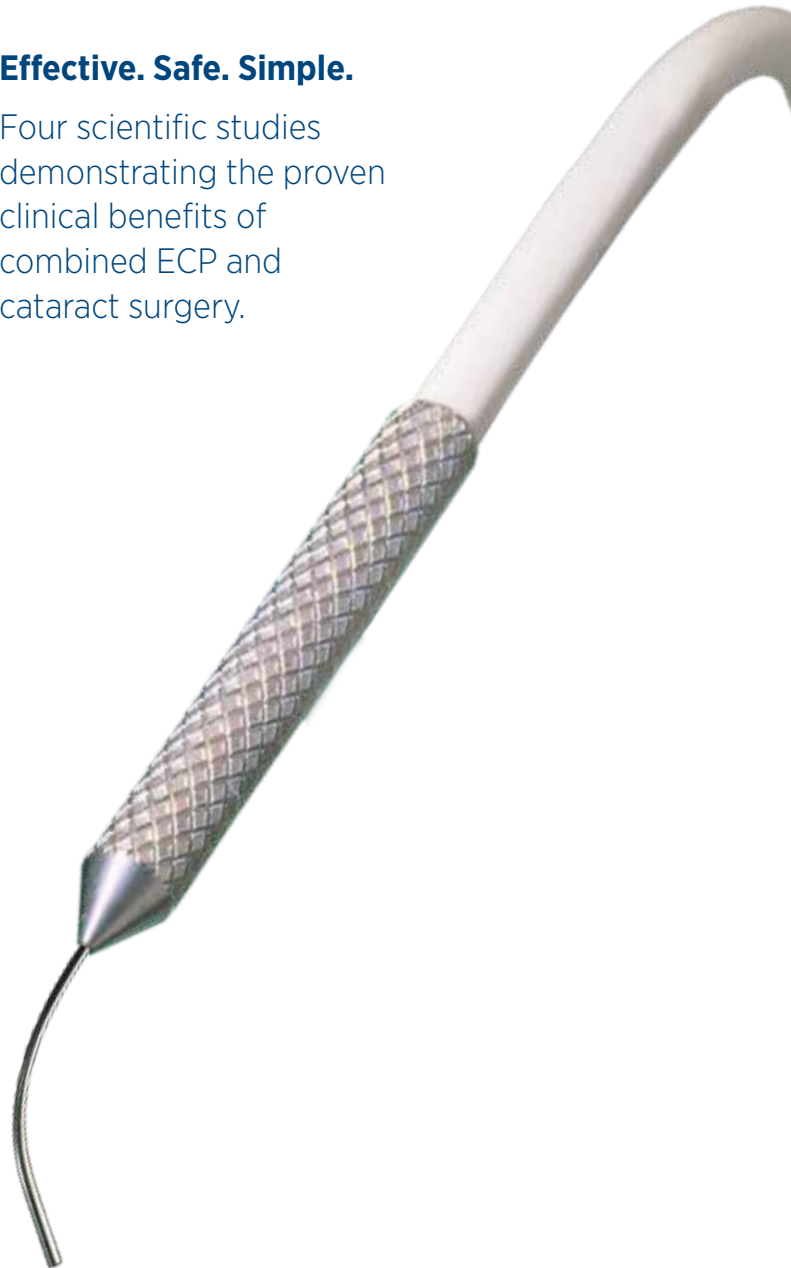
Endo Optiks®

Clinical Publication Summaries



Effective. Safe. Simple.

Four scientific studies demonstrating the proven clinical benefits of combined ECP and cataract surgery.



ECP is an Effective, Safe, and Simple Approach to Glaucoma Management

More than 3 million cataract surgeries are performed in the United States each year, and many of these patients are also being treated for glaucoma. Performing ECP in combination with cataract surgery has been clinically proven to lower your patients' intraocular pressure (IOP) long term and reduce the number of required glaucoma medications.

An abundance of clinical studies and data have been published documenting the outcomes of ECP. This brochure provides a high level overview of the benefits of introducing Endoscopic Cyclophotocoagulation to your practice by summarizing the information available in key clinical publications.




Table of Contents

Endoscopic Cyclophotocoagulation Combined With Phacoemulsification Versus Phacoemulsification Alone in Medically Controlled Glaucoma	5
Brian A. Francis, MD, MS, Stanley J. Berke, MD, Laurie Dustin, MS, Robert Noecker, MD <i>Journal of Cataract & Refractive Surgery, Volume 40, Number 8, August 2014</i>	
‘Phaco-ECP’: Combined Endoscopic Cyclophotocoagulation And Cataract Surgery to Augment Medical Control Of Glaucoma.....	7
Dan Lindfield, MD Robert W. Ritchie, MD Michael FP Griffiths, MD <i>BMJ Open 2012;2, April 2012</i>	
One-site Versus Two-site Endoscopic Cyclophotocoagulation	9
Malik Y. Kahook, MD, Kira L. Lathrop, MAMS Robert J. Noecker, MD <i>Journal of Glaucoma, Volume 16, Number 6, September 2007</i>	
Combined ECP and Cataract Surgery	11
Stanley J. Berke, MD, FACS <i>Cataract & Refractive Surgery Today Europe, Cover Story Page 1, October 2011</i>	



“Combined ECP-cataract extraction resulted in lower intraocular pressure & greater reduction in glaucoma medications than cataract extraction alone in medically controlled open angle glaucoma patients with visually significant cataract.”

— Brian A. Francis, MD, MS

Endoscopic Cyclophotocoagulation Combined With Phacoemulsification vs. Phacoemulsification Alone in Medically Controlled Glaucoma

Journal of Cataract & Refractive Surgery, Volume 40, Number 8, August 2014

Brian A. Francis, MD, MS
Stanley J. Berke, MD
Laurie Dustin, MS
Robert Noecker, MD

Summary and Conclusion

Combined ECP-cataract extraction resulted in lower IOP and greater reduction in glaucoma medications than cataract extraction alone in medically controlled open angle glaucoma patients with visually significant cataract. Baseline IOP = 18.1 mm Hg, 3 year IOP ECP/PE = 15.4 with <1 med, 3 year PE alone = 17.2 with 2 meds.

Purpose

To compare the outcomes of endoscopic cyclophotocoagulation (ECP) and phacoemulsification cataract extraction versus cataract extraction alone in eyes with medically controlled open-angle glaucoma (OAG) and visually significant cataract.

Setting

Clinical practices of glaucoma specialists and comprehensive ophthalmologists.

Design

Prospective nonrandomized matched-control study.

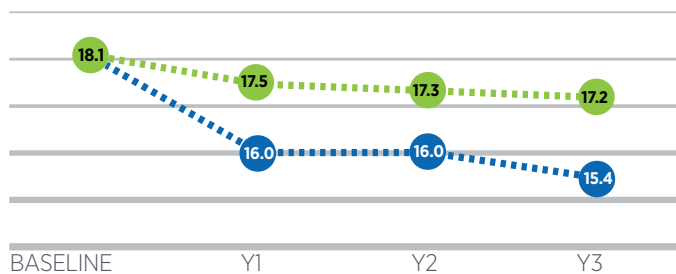
Methods

80 Consecutive patients were treated with ECP and cataract extraction (study group) or cataract extraction alone (control group). The groups were matched in age and baseline intraocular pressure (IOP). The main outcome measures were the change in IOP and number of glaucoma medications. Secondary measures included visual acuity and postoperative complications.

Results

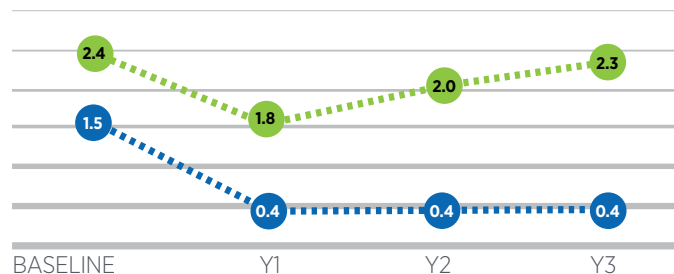
The difference in IOP and medication reduction between the 2 groups was statistically significant at all time points. Visual acuity outcomes and complication rates were similar between the 2 groups.

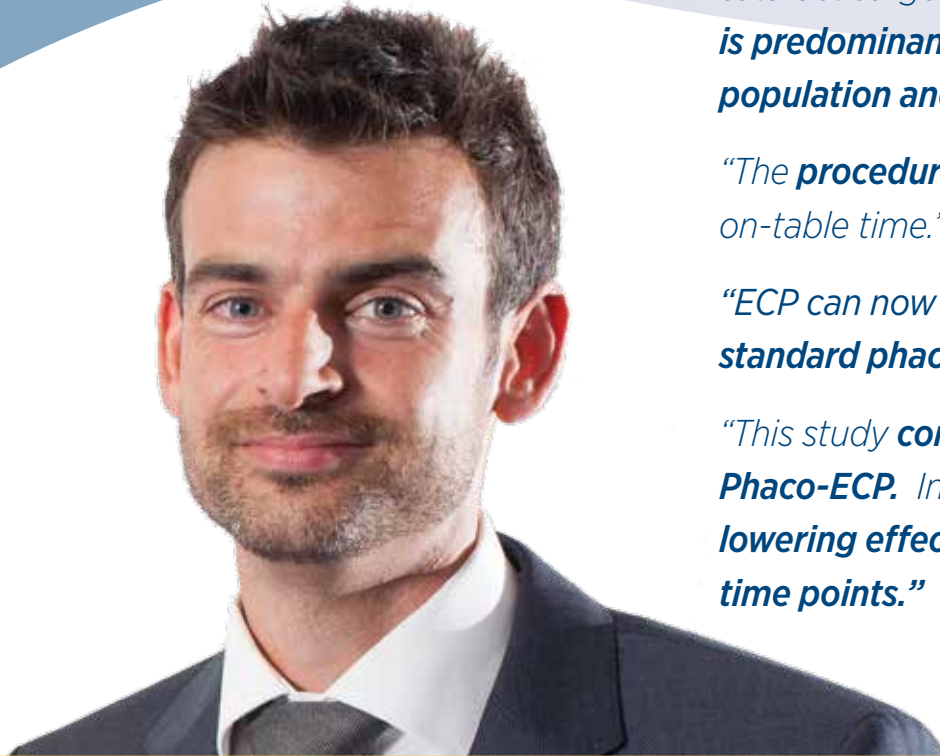Between Group Comparison of Pre-operative & Post-operative Mean IOP (mm Hg)



● Phaco + ECP
● Phaco Alone

Between Group Comparison of Pre-operative & Post-operative Glaucoma Medications





*“ECP combines almost symbiotically with cataract surgery. **Glaucoma, like cataract is predominantly a disease of the older population and is often concurrent.**”*

*“The **procedure adds 5 minutes** to the on-table time.”*

*“ECP can now be **performed through standard phaco incisions.**”*

*“This study **confirms the safety of Phaco-ECP.** In this case series, **the IOP lowering effect was significant at all time points.**”*

— Dan Lindfield, MD

Phaco-ECP: Combined Endoscopic Cyclophotocoagulation And Cataract Surgery to Augment Medical Control Of Glaucoma

BMJ Open 2012;2, April 2012

Dan Lindfield, MD
Robert W. Ritchie, MD
Michael FP Griffiths, MD

Summary and Conclusion

1.) Phaco-ECP is safe. 2.) ECP combines synergistically with cataract surgery. 3.) Phaco-ECP reduced IOP from 21.54 mm Hg (baseline) to 14.44 mm Hg (24 months) achieving statistical significance at all time points.

Purpose

To determine if Phaco-ECP reduces intraocular pressure (IOP) and if Phaco-ECP is safe.

Setting

Single District General Hospital Ophthalmology Department within the UK.

Design

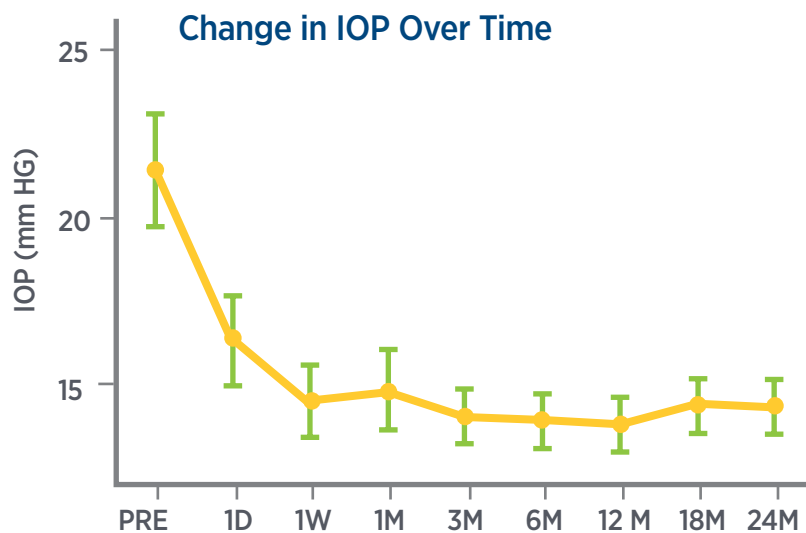
Retrospective case note review of all patients undergoing Phaco-ECP between June 08 — June 09. All glaucoma subtypes were included.

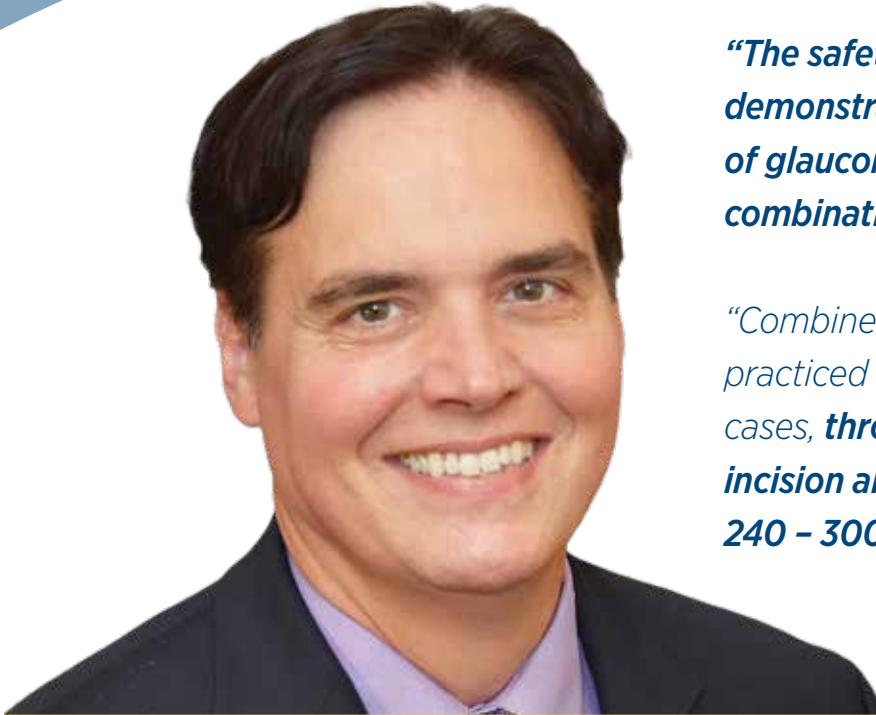Methods

58 participants case notes reviewed. Mean age 79.0 years. All patients received combined cataract surgery and endoscopic cyclophotocoagulation. Straight probe was used to photocoagulate at least 300 degrees of ciliary processes

Results

Mean pre-procedural IOP was 21.54 mm Hg (95% CI 1.68, n=56). A statistically significant decrease in IOP compared with pre-procedural IOP was demonstrated at all time points, beginning at 1 day following treatment. The mean IOP at 18 and 24 months was 14.43 mm Hg (95% CI 0.78, n = 53) and 14.44 (95% CI 0.81, n = 41), respectively. The mean difference in IOP from baseline to 18 and 24 months was 7.1 mm Hg ($p < 0.001$).





“The safety and efficacy of ECP has been demonstrated in treating various forms of glaucoma when performed alone or in combination with phacoemulsification.”

*“Combined Phaco-ECO is commonly practiced with ECP performed, in most cases, **through a single clear cornea incision allowing approximately 240 – 300 degrees of treatment.**”*

— Robert J. Noecker, MD

One-site Versus Two-site Endoscopic Cyclophotocoagulation

Journal of Glaucoma, Volume 16, Number 6, September 2007

Malik Y. Kahook, MD
Kira L. Lathrop, MAMS
Robert J. Noecker, MD

Summary and Conclusion

IOP data at 6 months showed that 2-site clear corneal incision during PE-ECP may result in statistically significant lower IOP, and less dependence on glaucoma meds versus 1-site. One-site treated between 240°-300°, 2-site treated 360°.

Purpose

To report the intraocular pressure (IOP) lowering effect of ECP treatment through 1 vs. 2 corneal incisions

Design

Retrospective nonrandomized study comparing data from consecutive patients who underwent 1-site (group 1) vs. 2-site (group 2) PE-ECP. Patients were selected for each group, equivalent in age, baseline IOP and number of medications.

Methods

Phacoemulsification was completed with in the bag placement of a posterior chamber IOL. Visco was then used underneath the iris to improve visualization of the ciliary processes. ECP was done using a curved probe. In the case of the single clear corneal incision, up to 300° was treated. With two incisions, 360° was treated. Irrigation/aspiration was then used to remove viscoelastic from the anterior chamber, the eye was pressurized with balanced salt solution, and the incisions were hydrated closed.

Results

IOP was significantly lower at all time points in Group 2 (2-site, 360°) vs. Group 1 (1-site, 240°-300°). No serious complications were noted in either group during the duration of the follow-up, specifically persistent hypotony, inflammation, endophthalmitis, corneal decompensations, macular edema or retinal detachment. Overtreatment is not possible. STUDY SHOWS LONG TERM IOP CONTROL, LESS DEPENDENCE ON TOPICAL MEDS, AND NO COMPLICATIONS POST OPERATIVELY.

Change in IOP From Baseline With 6 Months of Follow-up in Patients Undergoing One-site (Group 1) vs. Two-site (Group 2) ECP

Mean and SD	Group 1 (n=15)	Group 2 (n=25)	ANOVA
Preoperative IOP	23.60 +/- 3.89	24.48 +/- 8.99	<i>P</i> = 0.72
Postoperative day 30 IOP	18.93 +/- 3.71	14.84 +/- 2.85	<i>P</i> = 0.0004
Postoperative day 90 IOP	17.93 +/- 4.38	13.88 +/- 3.22	<i>P</i> = 0.002
Postoperative day 180 IOP	16.00 +/- 2.77	13.00 +/- 3.09	<i>P</i> = 0.04
	(n = 7)	(n = 13)	
Mean IOP decrease from baseline	5.27 +/- 4.85	11.20 +/- 9.35	<i>P</i> = 0.03

Comparison of Data From 1 Site (Group 1) Versus 2 Site (Group 2) ECP With 6 Months of Follow-up


Mean and SD	Group 1 (n=15)	Group 2 (n=25)	ANOVA
Age	66.07 +/- 17.73	73.48 +/- 11.31	<i>P</i> = 0.11
Preoperative medications	2.47 +/- 0.74	2.56 +/- 0.71	<i>P</i> = 0.70
Postoperative medications	1.93 +/- 0.88	0.52 +/- 0.59	<i>P</i> < 0.0001



Figure 1. Single-site ECP through clear cornea incision



Figure 2. ECP treatment through 2 sites showing the overlapping treatment underneath the primary clear cornea incision



“ECP is fun and interesting — The technology and the views are amazing.”

*“ECP provides the advantages of a direct view of ciliary process photocoagulation and **avoids the complications associated with transscleral cyclodestructive procedures.**”*

“Phaco-ECP resulted in a mean decrease in IOP and a reduction in glaucoma medications.”

— Stanley J. Berke, MD, FACS

Top Ten Reasons to Perform Combined Phaco-ECP

10: EASY TO DO

Adds only 2-4 minutes to the procedure.

9: TITRATABLE

No reports of hypotony or phthisis as a primary procedure with more than 1,000 cases with 5 years' follow-up and more than 50,000 cases worldwide in the past 10 years.

8: REPEATABLE

Can treat full 360° because the tips of the ciliary processes are treated, sparing the valleys in between.

7: VALUE ADDED FOR PATIENTS

Phaco-ECP is proven to further decrease IOP and the number of meds than phaco alone.

6: NO ADDITIONAL PATIENT FOLLOW UPS

Patients only need to be seen the same as phaco procedures alone post operatively, 1d, 1wk, 1m.

5: NO LONG TERM COMPLICATIONS

No incidents of hypotony, macular edema, or retinal detachment.

4: CONJUNCTIVA IS LEFT UNDISTURBED

If necessary, selective laser trabeculoplasty, repeat ECP, trabeculectomy or glaucoma drainage devices can be done subsequently.

3: NO EARLY OR LATE COMPLICATIONS

Unlike trabeculectomy or shunt procedures.

2: REIMBURSEABLE

In the US, CPT Code 06711 more than covers costs associated with the procedure for both surgeon and facility.

1: ECP IS FUN AND INTERESTING!

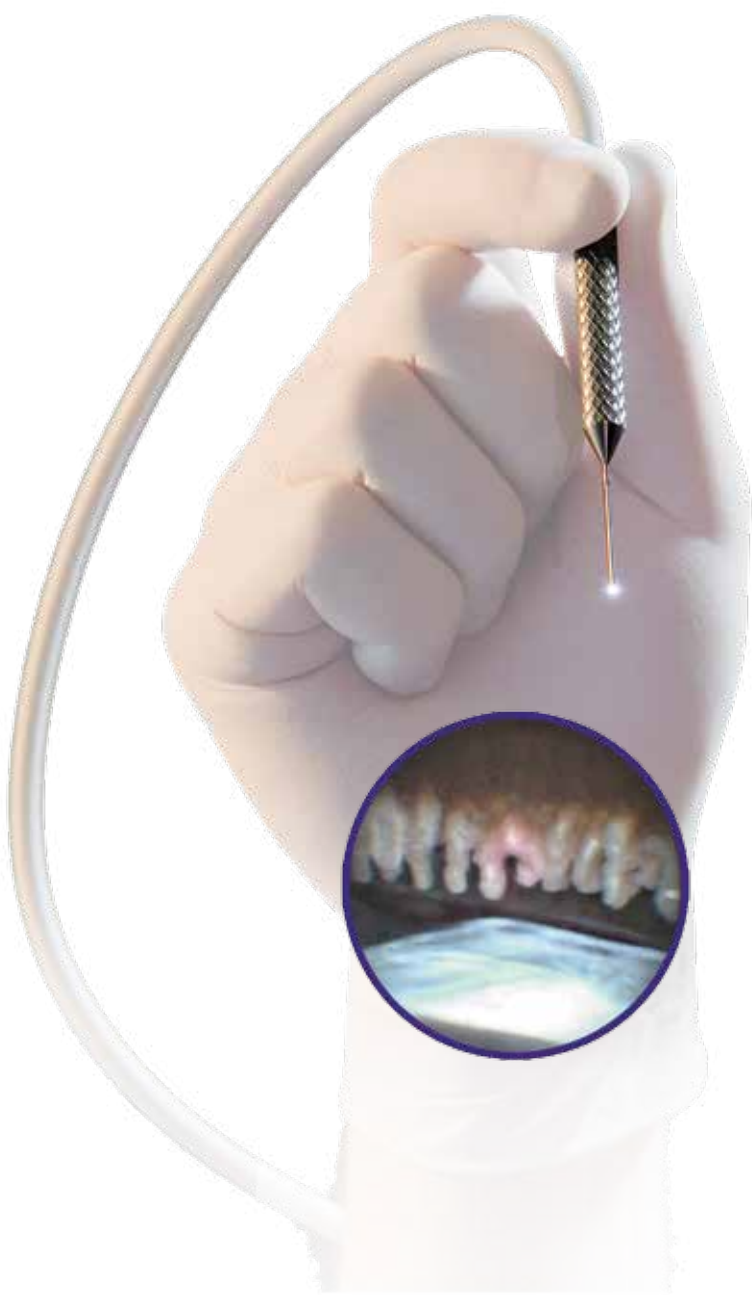A new view for surgeons, revealing a different look at cataracts, pathologic ciliary processes, zonules, capsular defects, etc.

Summary and Conclusion

- Laser and endoscopy permits the surgeon to observe the progress of tissue ablation.
- Combined Phaco-ECP resulted in a mean decrease in IOP and reduction of glaucoma meds.
- Treat at least 200° in every case, treating 270° to 300° is preferable.

Tips For Performing ECP

- Treat at least 200° in every case. Treating 270° to 300° is preferable and can be accomplished with a second clear corneal incision or with a curved endolaser probe.
- Treat the entire ciliary process from top to bottom, as well as the spaces between.
- Eyes with pseudoexfoliation are more difficult to treat and may require an increase in laser power, or moving the probe closer to the target tissue.
- Remove all OVD inside the eye after the procedure, including in front and behind the iris, as well as behind the IOL.
- Treat all patients with a topical glaucoma med and oral acetazolamide 500mg immediately after surgery. Monitor patients for postop IOP spikes within the first 24 hours and as early as 3 hours post op.
- Taper glaucoma meds if IOP is reduced from pre-operative level. It may take 4-6 weeks to see the full effect of ECP.
- Some Phaco-ECP patients appear exactly the same as phaco alone and can be treated with the standard regimen of topical steroid and NSAID four times daily for 2-3 wks. Other phaco-ECP patients may exhibit increased inflammation and should be treated more intensively with anti-inflammatory agents for a slightly longer period.





Beaver-Visitec International, Inc.

411 Waverley Oaks Road, Waltham, MA 02452
Tel: 1.866.906.8080 Fax: 1.866.906.4304
www.beaver-visitec.com

Beaver-Visitec International, Sales Limited

85c Park Drive, Milton Park,
Abingdon, Oxfordshire, OX14 4RY, UK
Tel: 44.1865.601.256 Fax: 44.1865.595.761